

Welsh pony, bite wounds

The 6 year old Welsh pony Mira (mare) was attacked on 13/6 by a stallion; big wounds in the neck and on the leg were the result. The day after the attack the veterinarian was no longer able to suture the wounds. A painkiller, vedaprofen (Quadrisol) and trimethoprim-sulphonamide (TMPS) powder antibiotics were prescribed. The next day the wounds were filled with pus and exudate, which were removed via an incision on 15/6 (\pm 2ltr). The following 4 days the wounds were cleansed with tap water and thereafter a woundspray was applied (Acederm). From the 5th day post-trauma colloidal silverwater was used, which cleaned the wounds, but made them too dry.

On 2/7 (19 days post-trauma) the veterinarian decided to start treatment with L-Mesitran Soft. This honey based gel product will create a moist wound environment, is antibacterial and promotes granulation (Overgaaauw, 2006).

Product: L-Mesitran Soft

Case study done by: Stable Karé and Y vd Brug, DVM, Noordwolde, The Netherlands

Method & Observations:

From the start with the honey gel the wounds were cleansed 1x/dy, after which the gel was applied 2x/dy. The wound was not covered with dressings. The mare was administered TMPS in the feed until 13/7/2009 2x/dy. The honey gel was not painful to the mare. After 10 days into the treatment she regained her appetite, because she could move her neck to the ground again. During daytime she was in the stables, because flies were attracted to the wounds.

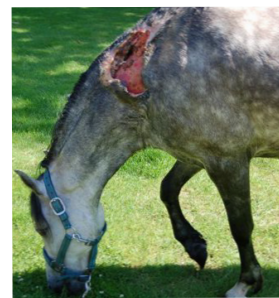On 13/7 the wound on the left measured \pm 125cm². The wound on the right was \pm 35cm² and \pm 2cm deep at the top. The muscle layer and the mane were separated. The wound bed was clean and granulating. The progress of the wound size reduction is depicted in figure 1. The wound on the right healed completely in 7½ weeks, the big wound on the left in 9 weeks. No infections or any adverse effects were observed.

Conclusion

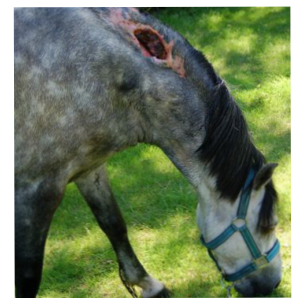
The use of antibiotics in the treatment of infected wounds of horses is still effective, but (similar to human use) the first signs of resistance are known (Clark, 2008). In this case it is evident that no new infection was seen within a \pm 7-9 week period when the mare had open wounds. The honey based gel prevented this (Swaim, 2008) and accelerated wound healing. The (daily) treatments were done by the owner of the horse, which indicates that this honey based product is a very easy and effective wound healing treatment *per secundam*.

References

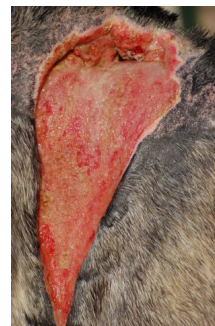- Clark C *et al.* (2008) Bacterial isolates from equine infections in western Canada (1998–2003). *Can Vet J* Vol 49(Feb): 153-160
- Overgaaauw P, Kirpensteijn J (2006) Application of honey in the treatment of skin wounds. *EJCAP* 16(1): 17-19
- Swaim S, Bohling M (2008) Advances in small animal wound management. *Veterinary Focus* Vol 18(1): 17-23



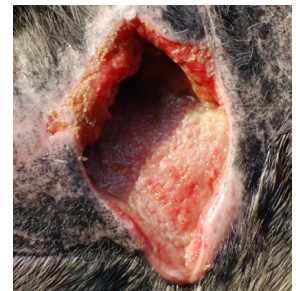Neck left, 24/6/2009



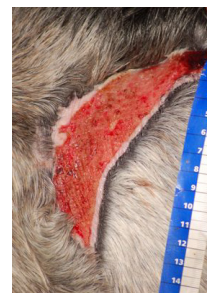Neck right, 24/6/2009



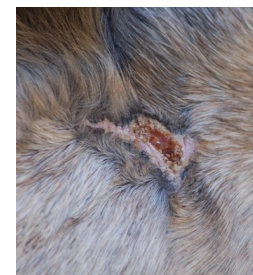Neck left, 3/7/2009



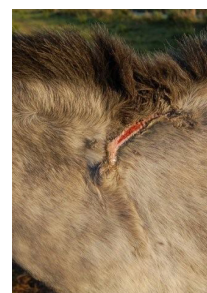Neck right, 3/7/2009



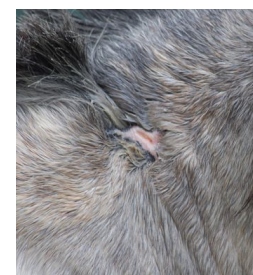Neck left, 24/8/2009



Neck right, 24/8/2009



Neck left, 3/10/2009



Neck right, 31/8/2009

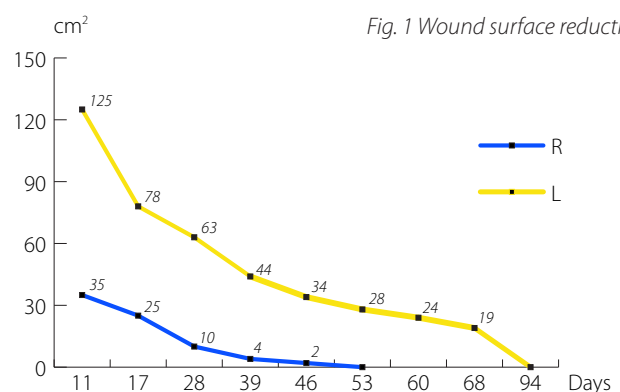


Fig. 1 Wound surface reduction.